

The International Journal of Esthetic Dentistry



SPECIAL REPRINT

Volume 13
Issue 4 • Winter 2018

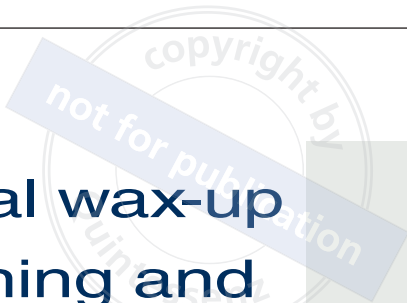Reza Saeidi Pour, Madalena Lucia Pinheiro
Dias Engler, Daniel Edelhoff, Otto Prandtner,
Stefan Frei, Anja Liebermann

A patient-calibrated individual wax-up as an essential
tool for planning and creating a patient-oriented
treatment concept for pathological tooth wear

 **HENRY SCHEIN®**
DENTAL

Access to this content is provided by: Henry Schein Dental
For more content provided by Henry Schein Dental visit
quintessence-partner.com





A patient-calibrated individual wax-up as an essential tool for planning and creating a patient-oriented treatment concept for pathological tooth wear

Reza Saeidi Pour, Dr med dent

Department of Prosthetic Dentistry, University Hospital, LMU Munich, Germany
Seehofer-Praxis für Zahnmedizin-Implantologie-Kieferorthopädie, Munich, Germany

Madalena Lucia Pinheiro Dias Engler, DDS, MSc

Dentistry Department, Federal University of Santa Catarina, Brazil

Daniel Edelhoff, Prof, Dr med dent

Department of Prosthetic Dentistry, University Hospital, LMU Munich, Germany

Otto Prandtner, MDT

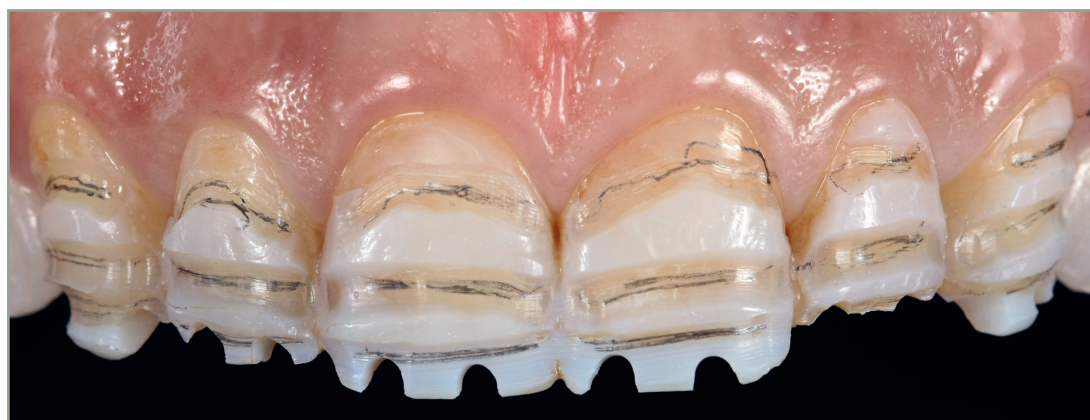Platform Laboratory, Munich, Germany

Stefan Frei, MDT

Platform Laboratory, Munich, Germany

Anja Liebermann, Dr med dent, MSc

Department of Prosthetic Dentistry, University Hospital, LMU Munich, Germany



Correspondence to: Dr Anja Liebermann

Department of Prosthetic Dentistry, University Hospital, LMU Munich, Goethestrasse 70, München, 80336, Germany;

Tel: +49 89 4400 59571; Email: Anja.Liebermann@med.uni-muenchen.de



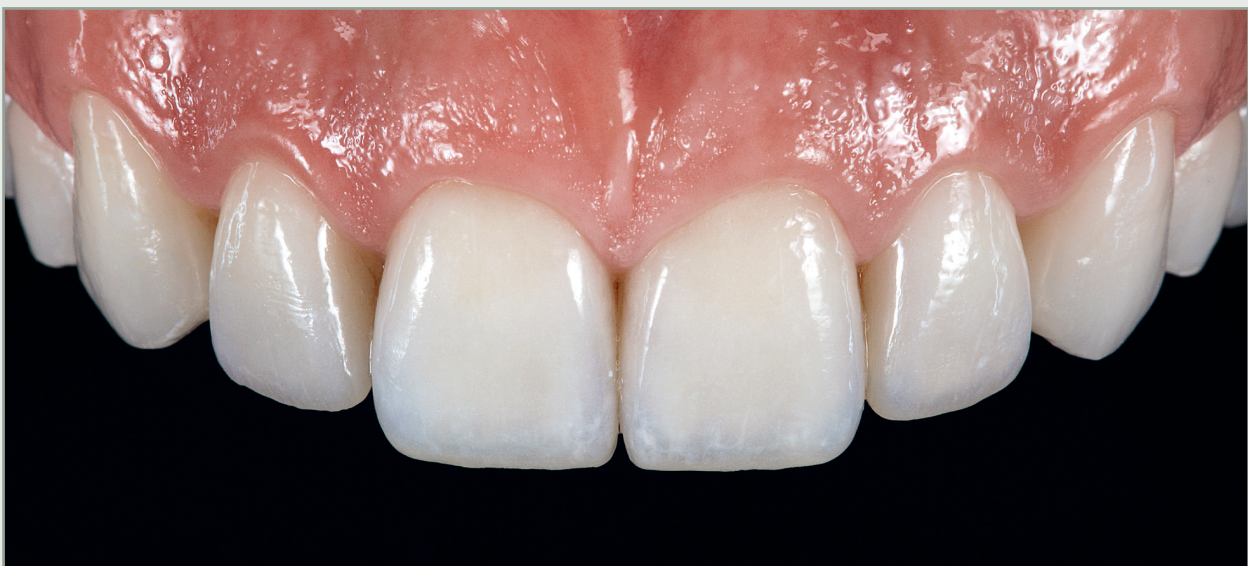copyright by
not for publication

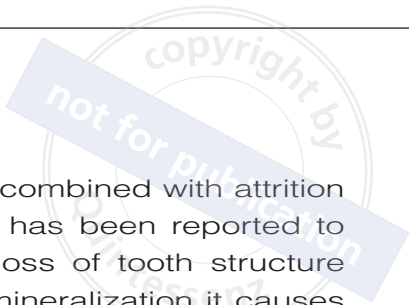
Abstract

Tooth wear is generally a physiological process; however, it can also be a pathological condition associated with attrition, abrasion, and erosion processes in which the quantity of tooth loss is atypical for the patient's age. Tooth substance loss often causes functional problems, symptoms of discomfort/pain, and esthetic impairments. Patients presenting this condition frequently need restorative treatment, combined with an increase in the vertical dimension of occlusion (VDO). A diagnostic wax-up (DWU) provides assistance in determining a new occlusal plane and VDO, and is a fundamental tool considering the backward planning involved in the execution of a complex rehabilitation. In cases of severe tooth wear, preventive measures must be taken. Yet, when a restorative intervention is needed, the use of a DWU,

in conjunction with a mock-up, helps to achieve a predictable and satisfactory outcome. This article presents a case report of a young female patient with pathological tooth wear, related symptomatology, and esthetic complaints. Initially, a DWU and a diagnostic mock-up were created. After esthetic and functional corrections, a second DWU was generated and transferred to the patient's mouth by means of a therapeutic mock-up. This mock-up was used as a trial restoration for the pretreatment phase, to evaluate the new VDO/esthetics/function and to guide tooth preparation. Lithium disilicate (LS2) occlusal onlays were used to stabilize the VDO, and anterior LS2 and feldspathic veneers, combined with direct composite restorations, were executed to reach the planned minimally invasive result.

(Int J Esthet Dent 2018; 13:476–492)





Introduction

Tooth wear and its consequences are a concern for dental teams. Tooth wear is generally a physiological process, usually presenting a low rate of tooth structure loss of 0.02 to 0.04 mm per year.¹ Epidemiological studies reveal that the prevalence of moderate tooth wear tends to increase with age.^{2,3} Tooth wear can, however, also be a pathological condition ('pathological tooth wear'), in which the quantity of tooth loss is atypical for the patient's age and mostly causes discomfort and/or pain, functional problems, and esthetic impairments. This condition is multifactorial and associated with processes such as attrition, abrasion, and erosion.³ Attrition is the tooth wear caused by the act of grinding the teeth against each other, mostly related to parafunctional habits and bruxism. Abrasion is related to the constant presence of an abrasion particle, as when excessive force is applied during brushing (toothpaste abrasives) or when tobacco is chewed.⁴ Dental erosion is a chemical process without bacterial association in which the teeth are exposed to acids that remove tooth structure. These acids originate from either extrinsic or intrinsic sources. Intrinsic sources arise from the individual, ie, a situation where endogenous acids such as gastric acid contact the teeth (eg, pathological conditions like bulimia or gastroesophageal reflux). Extrinsic sources are variable and mostly related to a person's ingestion habits.^{5,6} Continual exposure to acidic food and drinks seems to be the main cause of erosion nowadays, especially due to the high consumption of industrialized beverages such as soft drinks and energy

drinks.⁵ Erosion, combined with attrition and/or abrasion, has been reported to exacerbate the loss of tooth structure because the demineralization it causes softens the dental tissue, increasing the wear caused by mechanical processes.³ Since pathological tooth wear usually leads to a severe loss of tooth structure, patients presenting this condition often need restorative treatment that might be combined with an increase in the vertical dimension of occlusion (VDO),³ obtained when the maxillary and mandibular teeth are in contact (occluding). A prior assessment of the patient's VDO is made, and a decision to increase it usually results from a lack of space for an ideal restorative treatment, which includes the reinstallation of the tooth proportion and the restoration of an adequate static and dynamic occlusion.⁴

The diagnostic wax-up (DWU) is a fundamental tool for diagnostic treatment planning and transfer to a final rehabilitation in a patient with severe tooth wear. Apart from its use as a preparation guide, the DWU provides essential support in determining an adequate VDO as well as a clear visualization of function and esthetics.^{4,7} During treatment, the DWU is the main tool allowing the patient to visualize the possible treatment result. It is also one of the most important ways for the clinician, dental technician, and patient to communicate.⁸ The use of a preliminary wax-up for rehabilitation planning has been reported for decades⁹ and is considered irreplaceable for helping to answer fundamental questions that may arise during the pre-treatment phase, especially in complex cases where orthodontic and/or surgical interventions need to be combined



copyright by
not for publication
Quintessenz

in a multidisciplinary approach.¹⁰ Regarding esthetics, the development of a DWU should be guided by the patient's desires and needs, which must be completely clarified before any invasive intervention occurs. With references relating to the existing condition, and once the patient's desires are understood, the dental technician can execute a DWU. This can later be transferred to the patient's mouth by means of a mock-up, performed directly in the dental office using a silicone matrix and autopolymerizing resin.⁸ The mock-up can also be used as an interim restoration for a period of time, during which modifications of function and esthetics are possible. The mock-up serves as a guide for the preparation of the teeth during treatment. An additive wax-up, where the wax is added over the tooth surfaces in the cast to modify the current situation without any prior preparation, is recommended in conjunction with an additive mock-up for compensating the loss of tooth structure in patients with tooth wear.¹¹

This article presents a case report of a young female patient with pathological tooth wear, in which a DWU played an essential role from the planning and pretreatment phases through to executing the final rehabilitation.

Case report

A young female patient presented at the Department of Prosthetic Dentistry of the LMU München, complaining about the appearance of her smile (Figs 1 to 4). She presented worn dentition, extremely increased sensitivity to temperature (hot/cold food and drinks), and symptoms in



Fig 1 Preoperative appearance of the patient's smile.

static and dynamic occlusion. The following systematic sequence of steps was used for planning and executing the full-mouth prosthetic rehabilitation.

At the first visit, a complete anamnesis, a meticulous oral examination, a radiographic evaluation, and a functional analysis of the temporomandibular joints were made. The evaluation revealed the presence of different forms of tooth wear (Figs 3 and 4). The patient presented clinical signs of a combination of erosion, abrasion, and attrition (suspected bruxism). Information obtained from the anamnesis revealed that the patient was experiencing a stressful period and consuming excessive energy drinks. Study models, an arbitrary facebow record, registration in centric relation (CR), intra- and extraoral photographs, and a video recording were also obtained to complete the patient's



copyright by
not for publication
Christensen

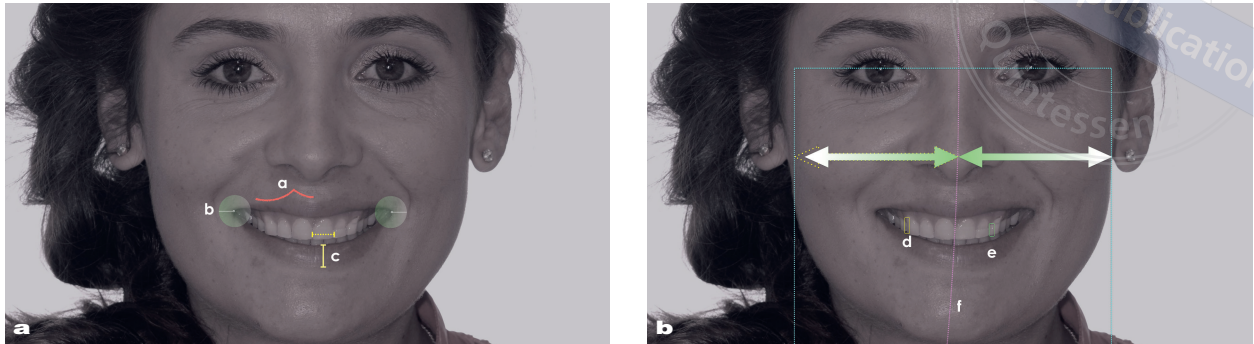

Fig 2 (a) a: Curved upper lip shape – bigger anterior tooth step; b: red part of the lips – guidance for width of maxillary central incisors; b: Corner of the mouth as indicator – higher raised side is the shorter facial half; c: Sign of asymmetry between both facial halves and the smile. (b) d, e: Alignment of maxillary canines as indicator for smaller and larger facial half. On the larger facial side is the distal part of the canine, aligned slightly outward. On the smaller facial side is the mesial part of the canine, aligned slightly outward; f: Indicator for the facial asymmetry and guidance for the midline direction.

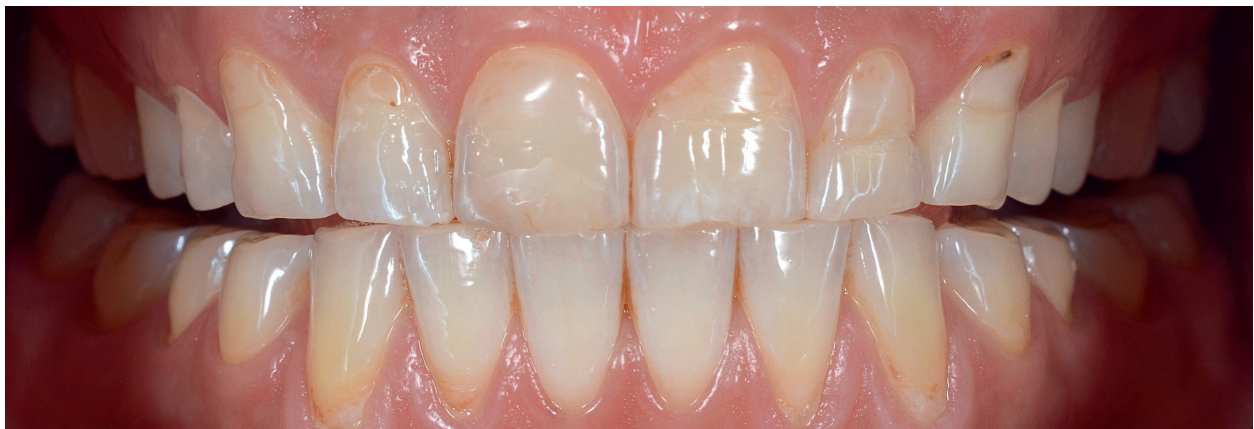

Fig 3 Presence of severe tooth wear on the buccal and incisal surfaces of the anterior teeth.

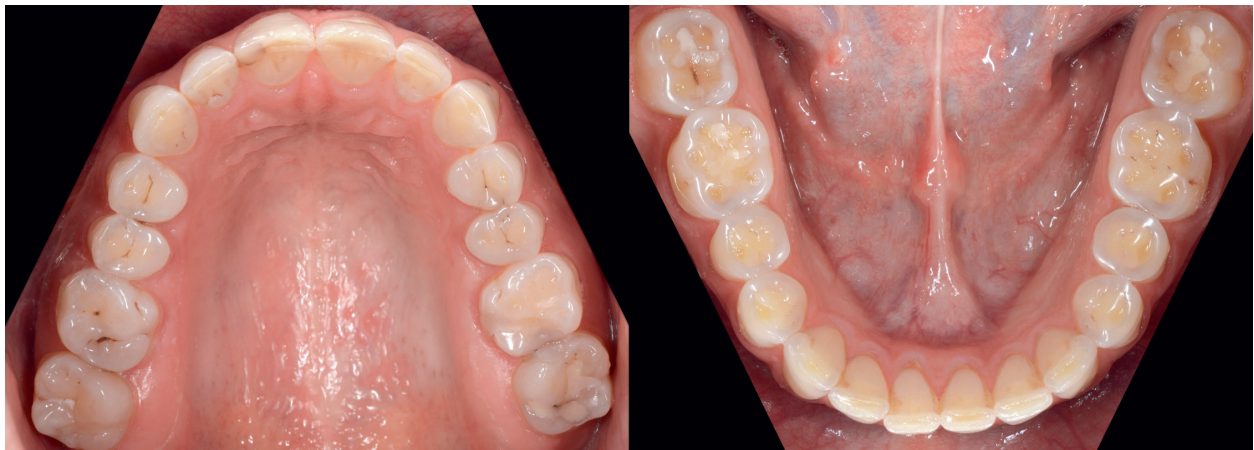

Fig 4 Presence of severe tooth wear on the occlusal surfaces of the posterior teeth with exposed dentin.

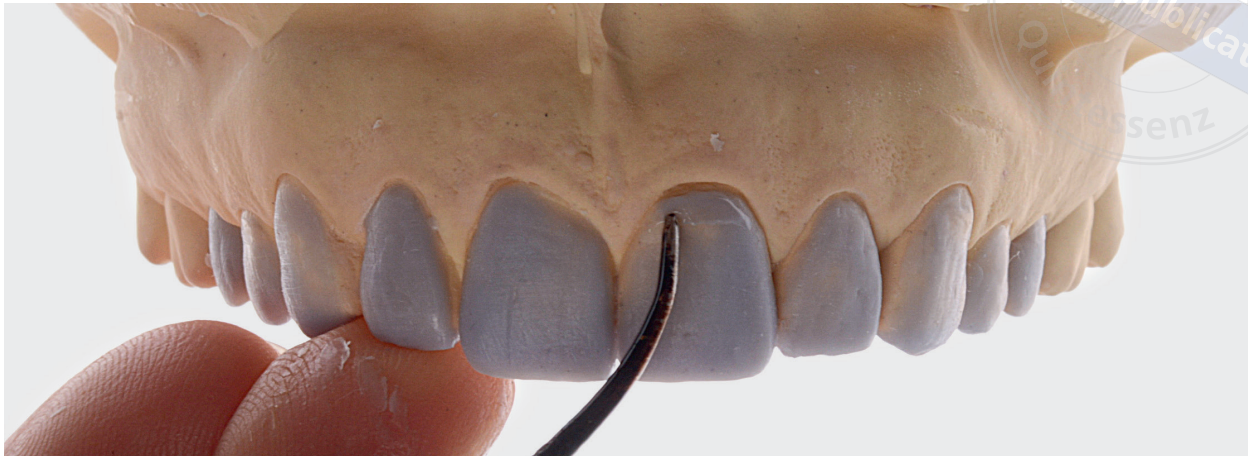

Fig 5 Final adjustments to the DWU, which generated the second wax-up.

dataset. The maxillary and mandibular study models were mounted in CR using a semi-adjustable articulator (Artex CR, Amann Girschbach).

All the collected data were used to create a DWU to determine the necessity of increasing the patient's VDO in order to obtain adequate space for the restorative treatment. Especially for restoring proper anterior canine guidance, the VDO was minimally increased by lifting the incisal pin of the articulator by 2.5 mm. The photographic documentation and analysis provided basic information about the esthetic appearance of the patient (Fig 2).

Determination of the VDO and diagnostic mock-up

The DWU was prepared with the new planned VDO and the new occlusal plane. The new VDO and esthetic design were transferred to the patient's mouth with a direct mock-up technique using autopolymerized resin (Protemp 5, 3M). A silicone matrix was prepared from a

thin layer of fluid silicone (shore 60, MATRIX Form 60 B, Anaxdent), and hardened in the pressure pot for increased accuracy. To enhance stability, the matrix was overlaid with a harder silicone (shore 85, Blue-Sil perfect 85, Weber Dental), and finally hardened in the pressure pot.

Autopolymerizing resin was poured into the matrix, which copied the DWU. The matrix was positioned in the patient's mouth to generate a mock-up. The posterior mock-ups were used to refine the planned VDO in a dynamic state using the speech method, whereby any occlusal contact detected during speech was marked and removed intraorally. A mock-up try-in was performed, with the complete restorative team discussing and noting all necessary corrections, including video and photographic documentation. Further corrections and adjustments of function and esthetics were made to the DWU in the dental laboratory, resulting in the second and final DWU (Figs 5 to 7 show detailed differences between the first and final

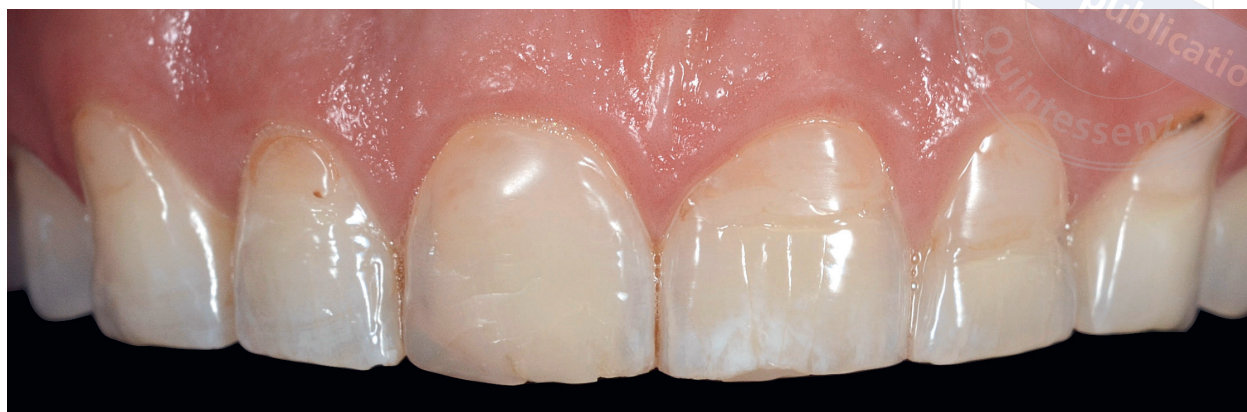

Fig 6 Maxillary anterior teeth before receiving the therapeutic mock-up.

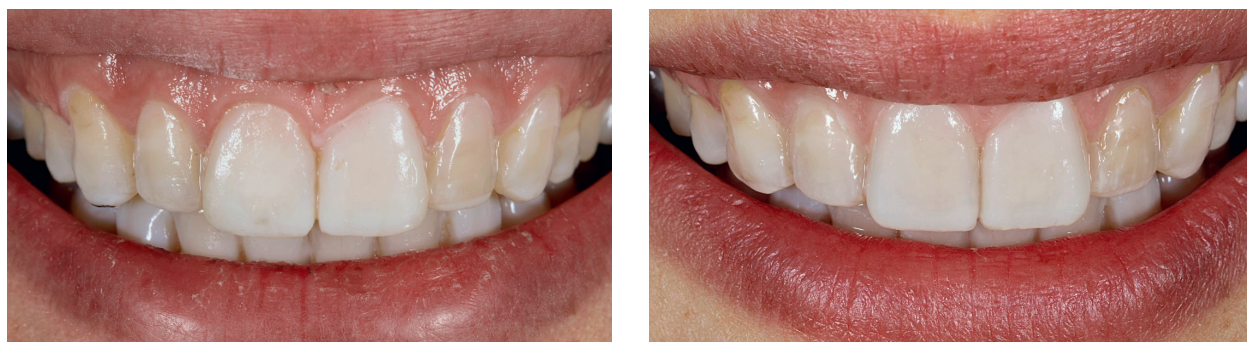

Fig 7 Therapeutic mock-up for the maxillary anterior teeth. Difference between the first and final mock-ups. Corrections involved the shortening of the maxillary right canine, extending the maxillary central incisors, and changing the shape of both maxillary canines.

mock-ups), which was used as a guide for the subsequent treatment steps and final rehabilitation.

Therapeutic mock-up

A new mock-up in correspondence with the final DWU was fabricated and fixed to the patient's teeth to serve as temporary restorations. During this step, the patient and the dental team evaluated the planned treatment (Figs 6 to 13). The following bonding procedures

were adopted for fixing the therapeutic mock-up: 1) Silica blasting of the areas with composite restorations (Co-Jet, 3M); 2) Spot etching of all teeth for 30 s with 37% phosphoric acid (Ivoclar Vivadent); 3) Rinsing for 30 s and air drying; 4) Applying coupling agent on the blasted areas (Monobond Plus, Ivoclar Vivadent); 5) Adhesive application: scrubbing for 20 s and light curing for 10 s. (Adhese Universal, Ivoclar Vivadent); 6) Positioning the resin-containing silicone index (Protemp 5); and



Copyright by
not for publication
Quintessence

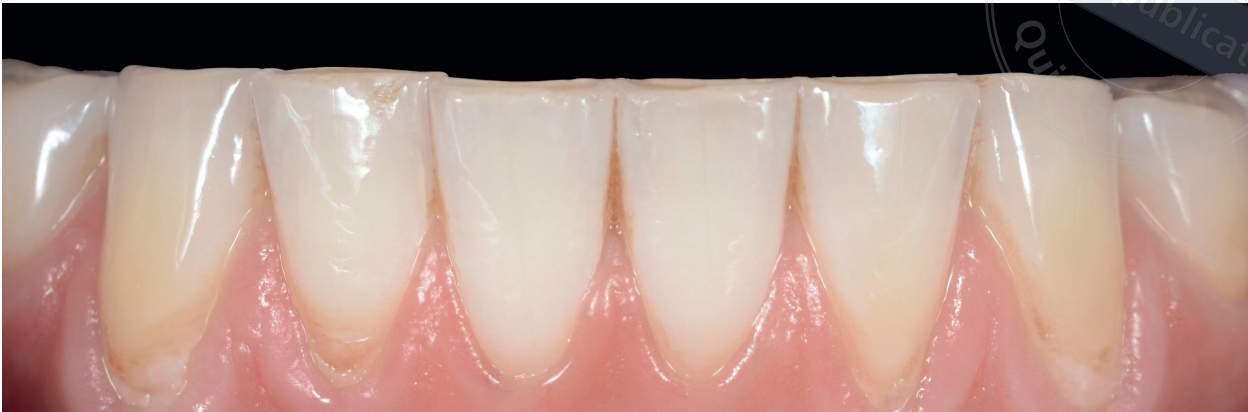

Fig 8 Mandibular anterior teeth before receiving the therapeutic mock-up.

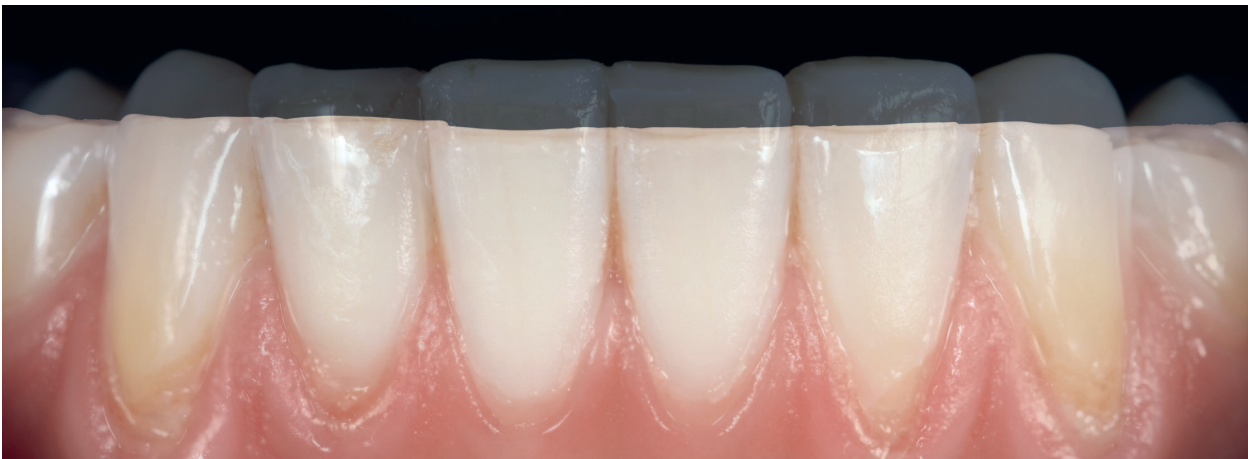

Fig 9 Therapeutic mock-up superimposed on the pretreatment situation, showing the contrast between the patient's tooth condition and the planned restorations.

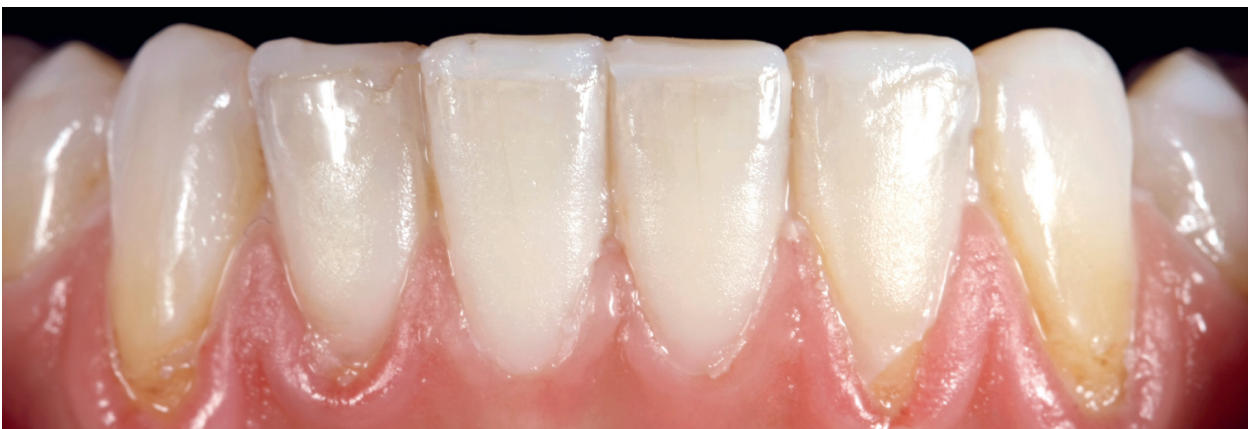

Fig 10 Therapeutic mock-up for the mandibular anterior teeth.

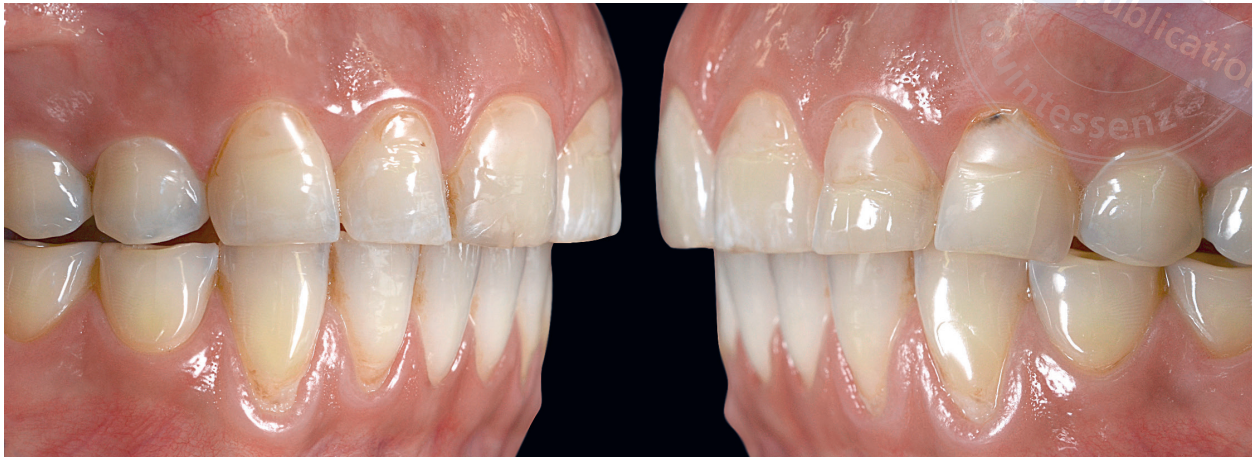

Fig 11 Lateral view of the pretreatment occlusal situation with the lack of canine guidance.

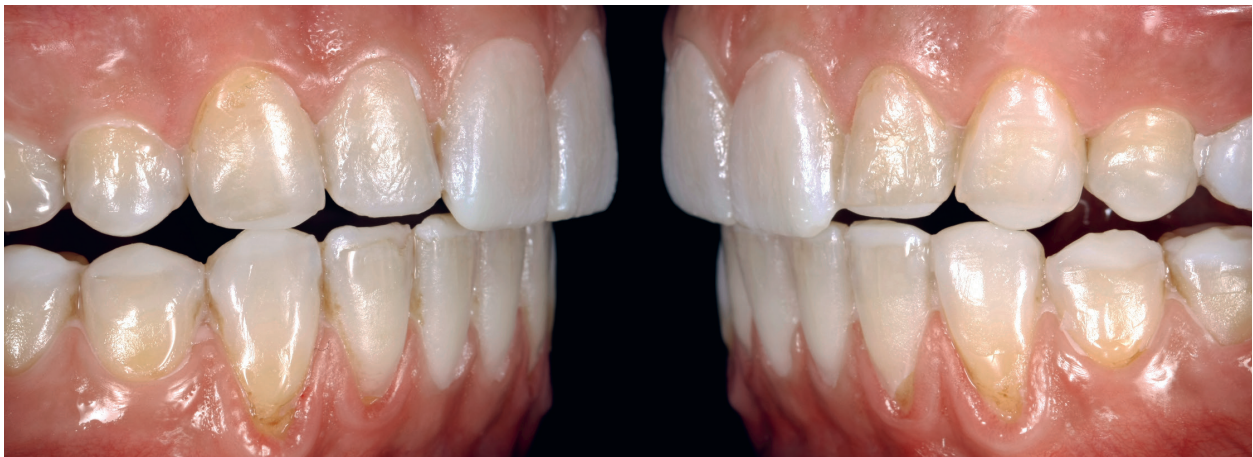

Fig 12 Lateral view of the occlusal situation after receiving the therapeutic mock-up, with the new planned canine guidance.

final light curing for 10 s. The therapeutic mock-ups bonded to the teeth showed the DWU that needed to be restored. The patient was able to adapt to the new increased VDO for 8 to 12 weeks. Within this interim period, no tooth preparations were performed, and the additive mock-up was retained without the occurrence of fractures. The patient reported relief from tooth sensitivity after the exposed dentin had been covered.

During this period of time, slight adjustments in static and dynamic occlusion were performed.

Preparation and rehabilitation

The first stage of the treatment involved restoring the posterior compartment to stabilize the new VDO. Preparations for the restoration were guided by the fixed therapeutic mock-up and performed on



Copyright by
Quintessenz
not for publication

the maxillary first and second premolars (occlusal buccal veneers) and mandibular premolars and molars (occlusal veneers/table tops) with lithium disilicate (LS2). These preparations were initiated over the mock-up. Depth marks were then prepared (Fig 14) and the mock-up removed. The preparation process continued without the mock-up, being guided by the depth marks to ensure the necessary minimum thicknesses for the future LS2 restorations: occlusal 1 mm, gingival third 0.3 mm, middle third 0.5 mm, and incisal third 0.7 mm. Full-arch polyether impressions (Impregum Penta, 3M) were obtained. The posterior LS2 (LiSi Press, GC) occlusal onlays were tried intraorally (Figs 15 and 16) with try-in paste (Variolink Esthetic, Ivoclar Vivadent), ultrasonically cleaned in 90% ethanol for 4 min, and prepared for bonding in the following steps: 1) Etching for 20 s (IPS Ceramic Etching Gel, Ivoclar Vivadent); 2) Rinsing and drying; 3) Coupling agent application (Monobond Plus); 4) Resin cement addition (Variolink Esthetic DC light). The



Fig 13 New appearance of the smile provided by the therapeutic mock-up.

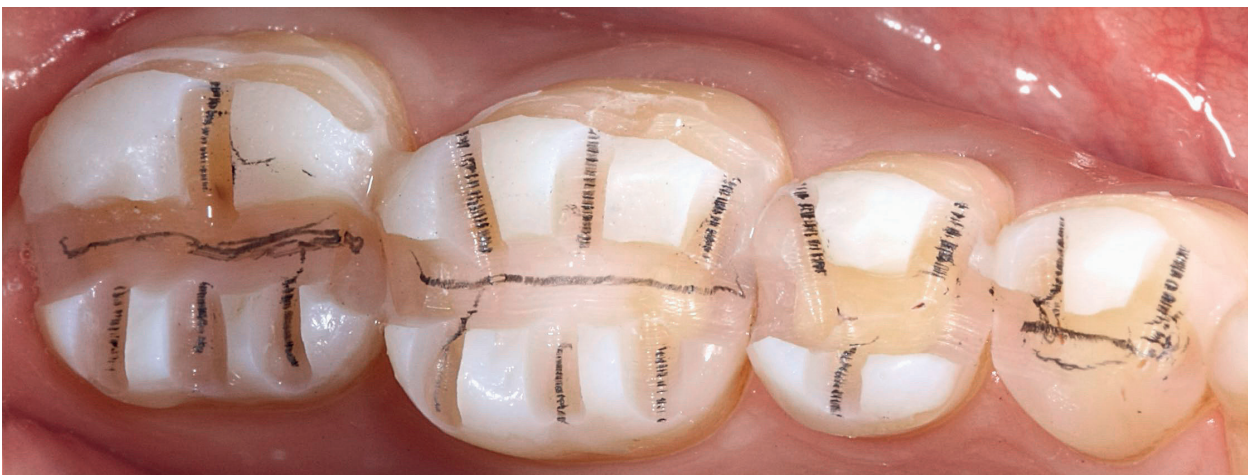

Fig 14 Preparation of the posterior teeth guided by the planning of the wax-up and mock-up.

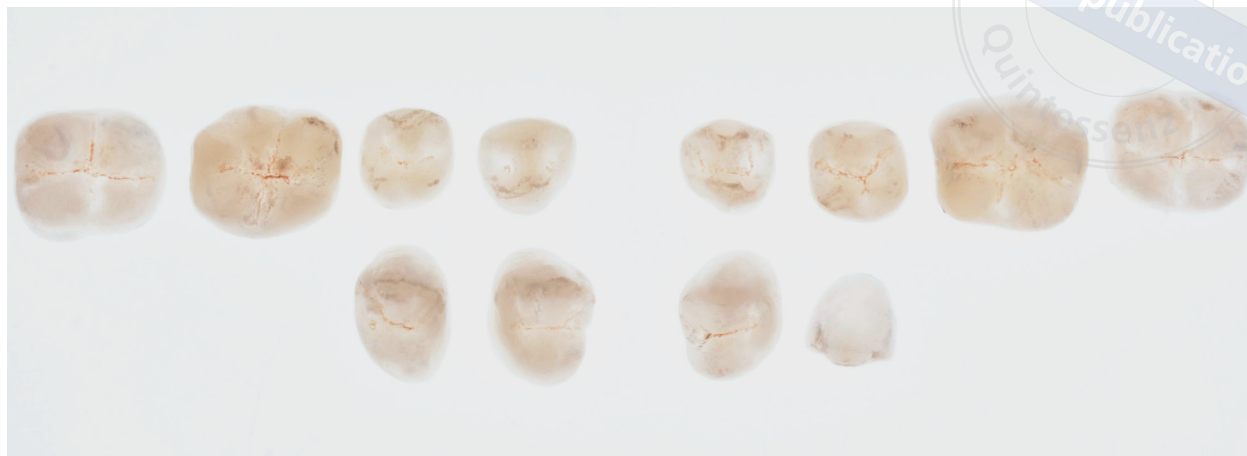

Fig 15 Posterior restorations fabricated from LS2.

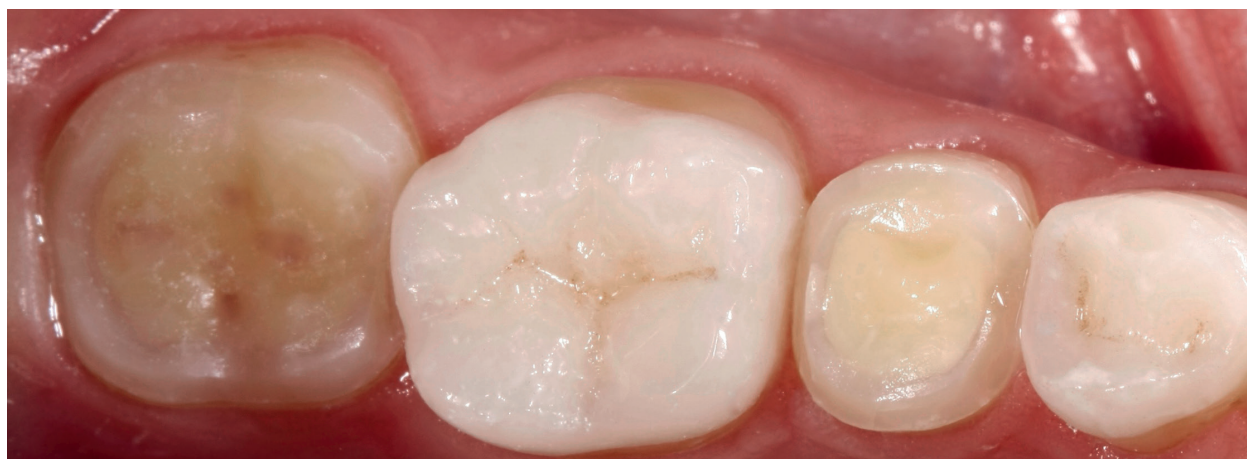

Fig 16 Try-in of the occlusal onlays with Try-In Paste (Ivoclar Vivadent).

teeth were prepared for bonding in the following steps: 1) Silicoating of the areas with composite restorations (CoJet); 2) Etching for 30 s on enamel and 15 s on dentin with 37% phosphoric acid (Ivoclar Vivadent); 3) Rinsing and drying; 4) Coupling agent application on air-abraded areas (Monobond Plus); 5) Adhesive application: scrubbing for 20 s (Adhese Universal); 6) Air cleaning to disperse the adhesive; 7) Light curing of the adhesive for 10 s; 8) Resin cement

addition (Variolink Esthetic DC – light) and onlay insertion; 9) Initial light curing for 5 s and removal of resin cement excesses; 10) Application of glycerin gel in the bonding interface areas (Liquid Strip, Ivoclar Vivadent); 11) Final light curing for 40 s on each side.

Bonding procedures were executed under absolute rubber dam isolation to avoid any contact with saliva or blood (Fig 17). With the new stabilized VDO, the second stage of the treatment



Copyright by
not for publication
Quintessence

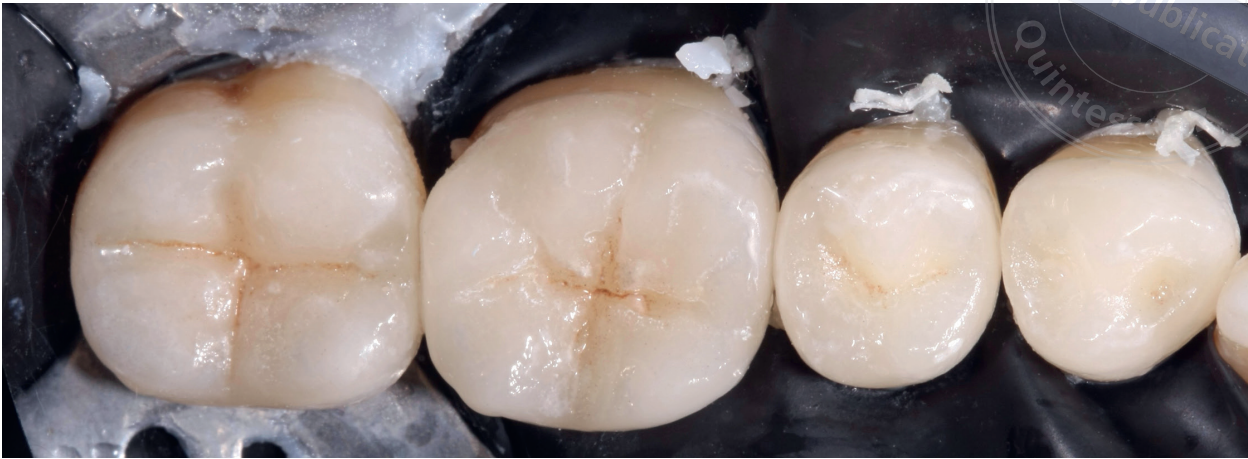

Fig 17 Bonding of the onlays under absolute rubber dam isolation to avoid any contamination with saliva.

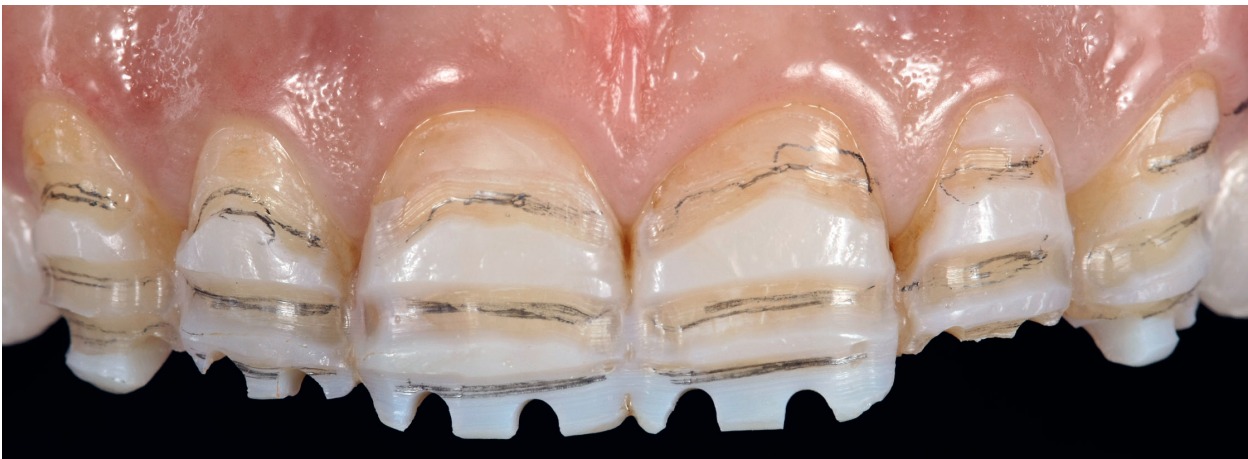

Fig 18 Preparation of the maxillary anterior teeth guided by the planning of the wax-up and mock-up.

phase was initiated with the restoration of the anterior compartment to recover esthetics and function. All six maxillary anterior teeth were prepared following the therapeutic mock-up and depth marking to ensure maximum preservation of healthy dental structure (Fig 18). The mandibular canines were also prepared for veneers, while the mandibular incisors received direct composite build-up restorations (Tetric EvoCeram, Ivoclar Vivadent). The maxillary and

mandibular canine veneers were fabricated from LS2 (IPS e.max Press, Ivoclar Vivadent) for higher strength in the canine guidance. Veneers for the maxillary incisors were fabricated from feldspathic ceramic (Creation CC, Willi Geller) (Fig 19). The anterior veneers were also tried intraorally with try-in paste, and bonded following the same protocol as described above for the LS2 onlays, except for the etching time of the feldspathic veneers (90 s) and the

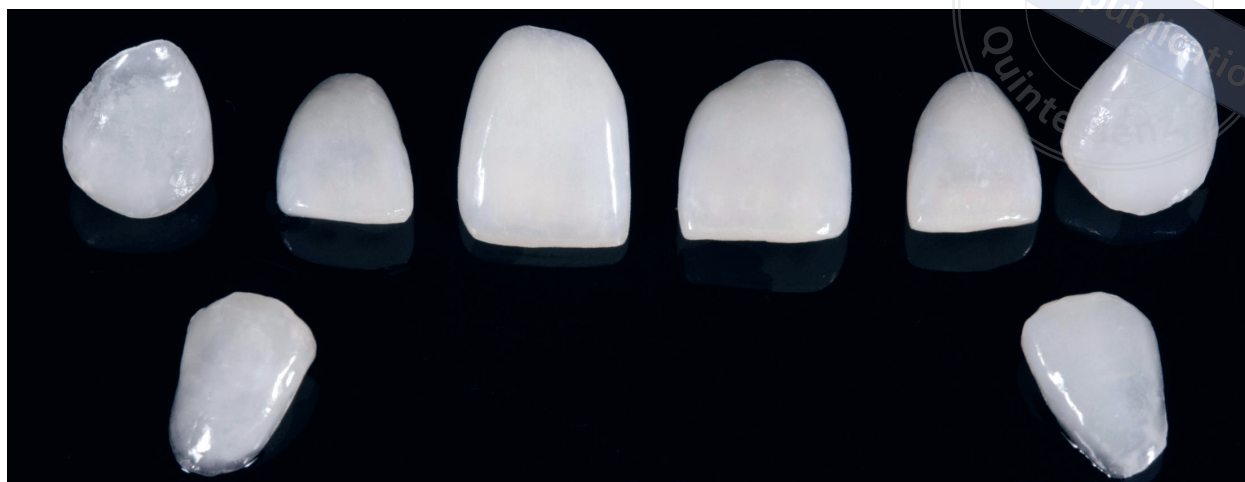

Fig 19 Anterior veneers fabricated from LS2 and feldspathic ceramic.

light-curing resin cement utilized (Variolink Esthetic LC – light). Figures 20 to 22 show the final aspect of the patient's smile.

Discussion

The presence of severe tooth wear is increasing nowadays, especially among younger people.¹² Gradation, classification, risk assessment, and progression monitoring are fundamental aspects of the decision-making process for managing tooth wear.¹⁶ Each case should be evaluated carefully and individually to assess the necessity of a treatment intervention or the possibility of simply applying preventive measures and monitoring the progression.

Since the etiology of tooth wear is multifactorial, the acknowledgment of the probability of wear progression will depend on the risk factors to which the patient is exposed.¹³ Erosive processes cause the enamel surface to

be softened due to chemical dissolution of hydroxyapatite, facilitating wear progression, especially when combined with the mechanical action of abrasion and attrition.³ It is therefore necessary to identify and control risk factors in order to achieve overall treatment success and long-term stability of the results by preventing recurrences of these processes in the future. Dietary habits (consumption of acidic foods and drinks), gastric reflux, vomiting eating disorders, and sleep and awake bruxism are the most common risk factors for erosion and attrition, respectively.^{3,14} This shows the complexity of treating tooth wear, since the treatment is multidisciplinary and demands complete commitment and compliance from the patient.

In the present case, the dietary habits of the patient were identified as the risk factor for erosion (ingestion of a high quantity of industrialized beverages), which, in combination with a too-strong brushing habit (causing abrasion) and the presence of attrition, led to a severely

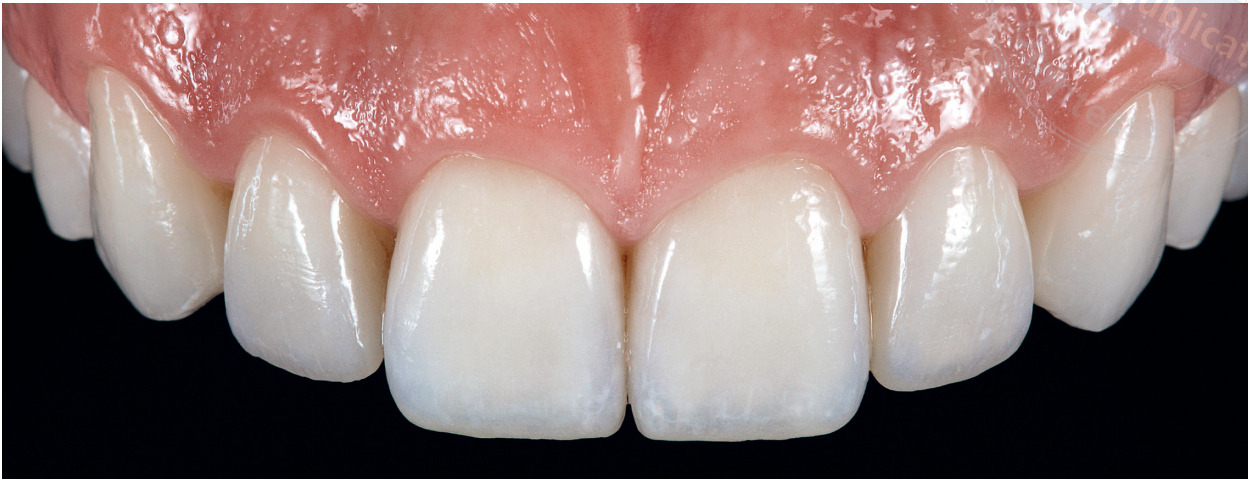copyright by
not for publication

Fig 20 Maxillary anterior teeth after bonding of the veneers.

worn dentition. The decision to perform restorative treatments is mostly based on patients' concern regarding symptomatology (mostly sensitivity), the integrity of their teeth, and the desire to restore the esthetic appearance and recover function.¹⁵ Wetselaar and Lobbezoo¹⁶ have provided a system to help the decision-making process in the management of

tooth wear by categorizing primary and secondary factors as reasons to start a treatment. Primary factors include the amount of tooth wear, the role of the affected surfaces, and whether the wear is localized or generalized. Secondary factors include etiological factors, the speed of wear progression, and the age of the patient. Wear progression can be

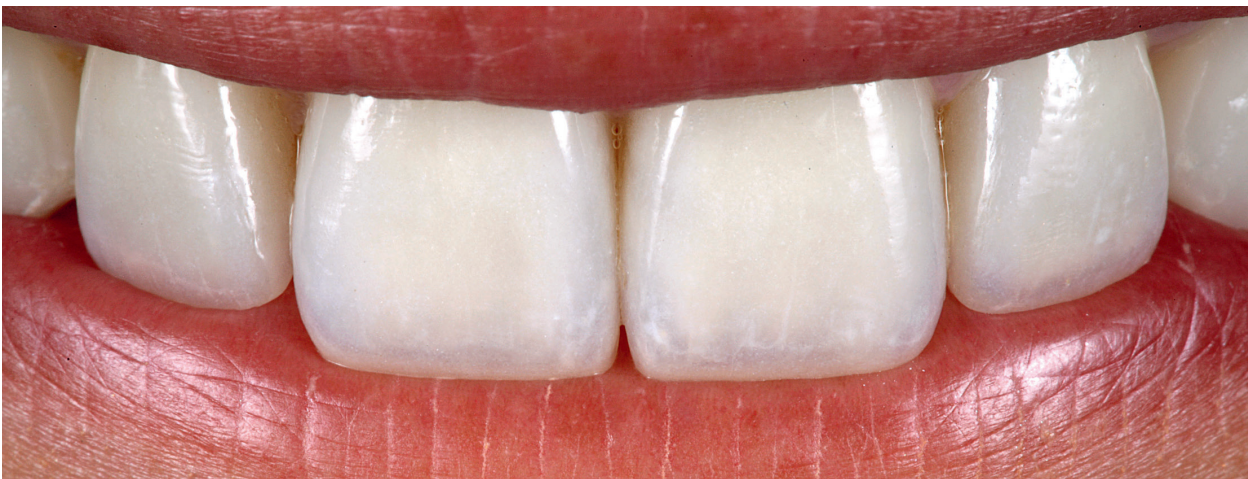

Fig 21 Postoperative appearance of the anterior tooth display in combination with lip dynamics.



Fig 22 Postoperative appearance of the patient's smile.

monitored by means of sequential impressions and casts or digital scanning of teeth surfaces over time.² The assessment of the other primary and secondary factors can also be made over time through clinical examination and a complete anamnesis.³ The evaluation of these factors, in conjunction with the patient's wishes, should lead to a decision as to whether a restorative intervention should be performed or a preventive approach chosen. In both cases, a careful follow-up of the patient will be necessary.

Restorative treatment of tooth wear is a complex task, often presenting the need for an increase in the VDO to obtain restorative space and restorations of a reasonable thickness.¹³ In the past, options for changing the VDO were frequently based on full-crown preparations; other

treatments such as orthodontic and surgical interventions were also applied. Today, with the advances in minimally invasive restorations, adhesive bonding techniques, and ceramic materials, occlusal veneer restorations have become a great option for restoring the VDO, with the main advantage of preserving healthy tooth structure.^{7,15,17} This possibility of minimally invasive intervention is recommended for patients with tooth wear, where the main purpose is to preserve healthy dental structure, and, by so doing, keep open other restorative options for the future.^{3,13} However, some cases may still require a multidisciplinary approach in conjunction with orthodontics or surgery. The DWU represents a practical and effective way of diagnosing the complexity of the treatment during the planning phase.^{10,18}

A DWU is by definition a dental diagnostic procedure in which the desired restorations are created in wax on diagnostic casts to determine the ideal clinical and laboratory procedures needed to achieve the functional and esthetic goals. A DWU can also help to determine the occlusal plane and the assessment of the correct height of the VDO that will be able to compensate for the loss of dental tissue and provide space for the anterior restorations.^{7,18} The DWU is performed by the dental technician based on objective and subjective parameters. Objective parameters include clinical guidelines relating to the type and extent of the planned restorations as well as basic standards of oral esthetics. Subjective parameters are based on the patient's personality and individual standard of oral esthetics. For this reason, the communication



between the patient and the dental technician is fundamental in the planning phase.¹⁹

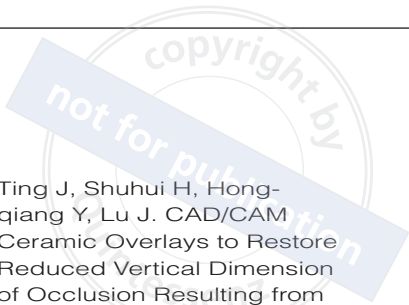
A DWU is also an efficient tool for communication between the clinician, the dental technician, and the patient, since it illustrates the expected treatment result and allows reversible modifications at any time. It transforms from a planning tool into a treatment tool by means of intraoral mock-ups. In general, mock-ups have two main purposes: 1) They allow the patient to return to daily life with temporary restorations and obtain people's opinions about his/her new teeth and smile, which increases the chances of patient acceptance of and compliance with the treatment; 2) They provide temporary restorations after tooth preparation in a fast and practical way at the dental office. Furthermore, in the presence of tooth wear and/or the application of a minimally invasive approach, the mock-up gains a third and essential purpose, which is to serve as a guide for minimally invasive tooth preparations.¹⁸ When designing the wax-up, the technician, respecting esthetic and functional parameters, completely reestablishes the initial volume of the teeth, sometimes even increasing it. This new designed volume will correspond to the thickness of the planned restorations, which will ensure that a conservative preparation is made. After the mock-up

(obtained from the wax-up) is bonded to the teeth, the preparation procedures are carried out with diamond burs, with predetermined depths on a precise guide that indicates the quantity and location of the tooth reduction – and this is the mock-up.^{20,21}

In the present case report, a preliminary DWU was made, generating a diagnostic mock-up. After corrections and refinements to this DWU, a second wax-up was developed, which provided the therapeutic mock-up that acted as an instrument for evaluation of the final treatment goal and the new planned VDO during the pretreatment phase. This guided the tooth preparation process.

Conclusion

Patients presenting severe tooth wear should be properly evaluated, correctly diagnosed, and carefully monitored, especially regarding the etiology of tooth wear. Primarily, preventive measures should be considered; however, when the esthetic and/or functional consequences affect a patient's quality of life, a restorative treatment is indicated. The use of a wax-up and mock-up to guide the treatment steps ensures the application of a minimally invasive approach and the achievement of a predictable and satisfactory result.



References

1. Hanif A, Rashid H, Nasim M. Tooth surface loss revisited: Classification, etiology, and management. *J Res Dent* 2015;3:37–43.
2. Ahmed KE, Whitters J, Ju X, Pierce SG, MacLeod CN, Murray CA. A Proposed Methodology to Assess the Accuracy of 3D Scanners and Casts and Monitor Tooth Wear Progression in Patients. *Int J Prosthodont* 2016;29:514–521.
3. Loomans B, Opdam N, Attin T, et al. Severe Tooth Wear: European Consensus Statement on Management Guidelines. *J Adhes Dent* 2017;19:111–119.
4. El-Kerdani T, Nimmo A. A Single Visit Direct Technique to Provisionally Restore Occlusion for a Full-Mouth Rehabilitation: A Clinical Report. *J Prosthodont* 2016;25:66–70.
5. Poggio C, Gulino C, Mirando M, Colombo M, Pietrocola G. Preventive effects of different protective agents on dentin erosion: An *in vitro* investigation. *J Clin Exp Dent* 2017;9:e7–e12.
6. Manaf ZA, Lee MT, Ali NH, et al. Relationship between food habits and tooth erosion occurrence in Malaysian university students. *Malays J Med Sci* 2012;19:56–66.
7. Gargari M, Lorè B, Ceruso FM. Esthetic and function rehabilitation of severely worn dentition with prosthetic-restorative approach and VDO increase. Case report. *Oral Implantol (Rome)* 2014;7:40–45.
8. Sancho-Puchades M, Fehmer V, Hämmerle C, Sailer I. Advanced smile diagnostics using CAD/CAM mock-ups. *Int J Esthet Dent* 2015;10:374–391.
9. Braly BJ. A preliminary wax-up as a diagnostic aid in occlusal rehabilitation. *J Prosthet Dent* 1966;16:728–730.
10. Spear FM, Kokich VG. A multidisciplinary approach to esthetic dentistry. *Dent Clin N Am* 2007;51:487–505.
11. Reshad M, Cascione D, Magne P. Diagnostic mock-ups as an objective tool for predictable outcomes with porcelain laminate veneers in esthetically demanding patients: a clinical report. *J Prosthet Dent* 2008;99:333–339.
12. Li Z, Yang Z, Lan T, Zhao H, Liu Y. Worn is born: The role of the maxillo-mandibular relation in management of worn dentition. *Med Hypotheses* 2017;104:156–159.
13. Loomans BAC, Kreulen CM, Huijs-Visser HECE, et al. Clinical performance of full rehabilitations with direct composite in severe tooth wear patients: 3.5 years results. *J Dent* 2018;70:97–103.
14. Al-Zwaylif LH, O'Toole S, Bernabé E. Type and timing of dietary acid intake and tooth wear among American adults [epub ahead of print 11 Jan 2018]. *J Public Health Dent* 2018. doi: 10.1111/jphd.12264.
15. Ting J, Shuhui H, Hong-qiang Y, Lu J. CAD/CAM Ceramic Overlays to Restore Reduced Vertical Dimension of Occlusion Resulting from Worn Dentitions: A Case History Report. *Int J Prosthodont* 2017;30:238–241.
16. Wetselaar P, Lobbezoo F. The tooth wear evaluation system: a modular clinical guideline for the diagnosis and management planning of worn dentitions. *J Oral Rehabil* 2016;43:69–80.
17. Fradeani M, Barducci G, Bacherini L, Brennan M. Esthetic rehabilitation of a severely worn dentition with minimally invasive prosthetic procedures (MIPP). *Int J Periodontics Restorative Dent* 2012;32:135–147.
18. Simon H, Magne P. Clinically based diagnostic wax-up for optimal esthetics: the diagnostic mock-up. *J Calif Dent Assoc* 2008;36:355–362.
19. Magne P, Magne M, Belser U. The diagnostic template: a key element to the comprehensive esthetic treatment concept. *Int J Periodontics Restorative Dent* 1996;16:560–569.
20. Magne P, Belser UC. Novel porcelain laminate preparation approach driven by a diagnostic mock-up. *J Esthet Restor Dent* 2004;16:7–18.
21. Coachman C, Gurel G, Calamita M, Morimoto S, Paolucci B, Sesma N. The influence of tooth color on preparation design for laminate veneers from a minimally invasive perspective: case report. *Int J Periodontics Restorative Dent* 2014;34:453–459.